Utilizing a Concentrated Surfactant to disrupt biofilm, decrease time to wound closure

Macdonald's HOME HEALTH CARE

Lauren Wolfe RN, BSN, MClSc-WH, CWOCN
Macdonald's Prescriptions Fairmont Building

Statement of Clinical Problem:

Biofilms are complex communities of bacteria encased by an extracellular matrix. This extracellular matrix can demonstrate delayed wound healing. Despite the multitude of antimicrobial dressings, limited dressings disrupt biofilm.

Significance to practice:

Delayed wound closure increases costs to the health care system (or patient). Quality of life is affected. Four case studies demonstrate that applying a concentrated surfactant disrupted biofilm, and time to closure shortened.

Case Study 1

77-year-old man with a traumatic injury to his forefoot. Comorbidities included Diabetes Type 2

Tx: Offloading, and moisture balance utilizing a concentrated surfactant

1 month later

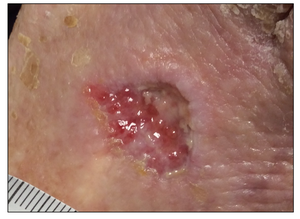

Case Study 2

75-old man with a chronic venous leg ulcer. Comorbidities included obesity, and previous DVT. Unknown previous wound management. Initial wound care management was an antimicrobial dressing.

Tx: Compression and antimicrobial moisture balance with utilizing a concentrated surfactant

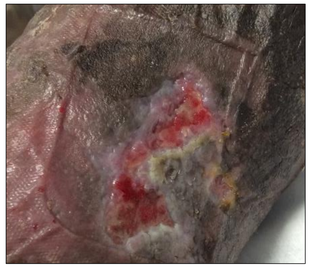

2 weeks later

Case Study 3

76-year-old man with an infected left leg traumatic injury. Comorbidities included decreased calf muscle pump and venous insufficiency. Initial management was a combination of antimicrobial packing and foam dressings.

Tx: Compression and antimicrobial moisture balance with utilizing a concentrated surfactant

5 weeks later

Case Study 4

78-year-old man with a DFU to his right heel. Comorbidities included Type 2 DM, HTN, COPD, left hip and right knee replacement, OSA, venous insufficiency. Initially treated with an iodine solution when he sought alternative management.

Tx: Offloading, CSWD of callus, compression and antimicrobial moisture balance with utilizing a concentrated surfactant

2 weeks later

Findings:

Three wounds demonstrated improvement and closure with applying a concentrated surfactant. One wound showed significant improvement; however, the dressing was switched to an ECM (Extracellular Matrix) dressing until closure due to multiple offloading concerns.

Conclusion:

Stalled wounds may have a biofilm present. Biofilm is not visible to the naked eye. When a wound does not follow the wound healing trajectory in demonstrating continued progression, the clinician should consider a product that has an affect on a biofilm if all other factors affecting wound care have been addressed

References:

Medline. (2019). *PluroGel The science and innovation behind wound management with PluroGel.*

Schultz, G., Bjarnsholt, T., James, G. A., Leaper, D. J., McBain, A. J., Malone, M., … Wolcott, R. D. (2017). Consensus guidelines for the identification and treatment of biofilms in chronic nonhealing wounds. *Wound Repair and Regeneration*, *25*(5), 744–757. https://doi.org/10.1111/wrr.12590

Swanson, T., & Angel, D. (2016). Wound Infection in Clinical Practice Update. In *International Wound Infection Institute (IWII) Wound infection in clinical practice. Wounds International 2016 Sponsored.*